

## Sciatica of nondisc origin and piriformis syndrome: diagnosis by magnetic resonance neurography and interventional magnetic resonance imaging with outcome study of resulting treatment

AARON G. FILLER, M.D., PH.D., JODEAN HAYNES, B.A., SHELDON E. JORDAN, M.D., JOSHUA PRAGER, M.D., J. PABLO VILLABLANCA, M.D., KEYVAN FARAHANI, PH.D., DUNCAN Q. MCBRIDE, M.D., JAY S. TSURUDA, M.D., BRANNON MORISOLI, B.A., ULRICH BATZDORF, M.D., AND J. PATRICK JOHNSON, M.D.

*Institute for Spinal Disorders, Cedars Sinai Medical Center, Los Angeles; Division of Neurosurgery, Departments of Anesthesia, Neurology and Radiology, and School of Medicine, University of California at Los Angeles; and Neurography Institute and Institute for Nerve Medicine, Santa Monica, California*

**Object.** Because lumbar magnetic resonance (MR) imaging fails to identify a treatable cause of chronic sciatica in nearly 1 million patients annually, the authors conducted MR neurography and interventional MR imaging in 239 consecutive patients with sciatica in whom standard diagnosis and treatment failed to effect improvement.

**Methods.** After performing MR neurography and interventional MR imaging, the final rediagnoses included the following: piriformis syndrome (67.8%), distal foraminal nerve root entrapment (6%), ischial tunnel syndrome (4.7%), discogenic pain with referred leg pain (3.4%), pudendal nerve entrapment with referred pain (3%), distal sciatic entrapment (2.1%), sciatic tumor (1.7%), lumbosacral plexus entrapment (1.3%), unappreciated lateral disc herniation (1.3%), nerve root injury due to spinal surgery (1.3%), inadequate spinal nerve root decompression (0.8%), lumbar stenosis (0.8%), sacroiliac joint inflammation (0.8%), lumbosacral plexus tumor (0.4%), sacral fracture (0.4%), and no diagnosis (4.2%).

Open MR-guided Marcaine injection into the piriformis muscle produced the following results: no response (15.7%), relief of greater than 8 months (14.9%), relief lasting 2 to 4 months with continuing relief after second injection (7.5%), relief for 2 to 4 months with subsequent recurrence (36.6%), and relief for 1 to 14 days with full recurrence (25.4%). Piriformis surgery (62 operations; 3-cm incision, transgluteal approach, 55% outpatient; 40% with local or epidural anesthesia) resulted in excellent outcome in 58.5%, good outcome in 22.6%, limited benefit in 13.2%, no benefit in 3.8%, and worsened symptoms in 1.9%.

**Conclusions.** This Class A quality evaluation of MR neurography's diagnostic efficacy revealed that piriformis muscle asymmetry and sciatic nerve hyperintensity at the sciatic notch exhibited a 93% specificity and 64% sensitivity in distinguishing patients with piriformis syndrome from those without who had similar symptoms ( $p < 0.01$ ).

Evaluation of the nerve beyond the proximal foramen provided eight additional diagnostic categories affecting 96% of these patients. More than 80% of the population good or excellent functional outcome was achieved.

**KEY WORDS** • sciatica • piriformis syndrome • magnetic resonance neurography • open magnetic resonance imaging • outcome study

**T**HE independent point prevalence of sciatica in the adult population is greater than 5%<sup>32</sup> and its lifetime prevalence is as high as 40%.<sup>28</sup> The percentage of these cases of sciatica caused by lumbar disc herniations, however, remains unclear. Lumbar spine surgery is performed annually in only approximately 0.2%<sup>6,60</sup> of this population.

*Abbreviations used in this paper:* CT = computerized tomography; FSE = fast-spin echo; MR = magnetic resonance; ODI = Oswestry Disability Index; RSD = reflex sympathetic dystrophy; SLR = straight leg raising.

Prior to 1934, sciatica was viewed primarily as the result of sciatic nerve entrapment in the pelvis,<sup>27,43,63</sup> but Mixter and Barr's widely respected publication<sup>47</sup> revealed the clinical importance of lumbar disc herniation. New diagnostic technology is now able to demonstrate that many cases of sciatica are in fact due to causes unrelated to disc lesions<sup>49</sup> such as piriformis syndrome and distal foraminal impingements.

Because of methodological flaws, many of these diagnoses have not been adequately considered despite two decades of high-quality epidemiological and clinical work in this field. In one report written by a leading group of

epidemiologists sciatica is defined as “. . . symptoms and findings considered to be secondary to herniations of a lumbar disc.”<sup>52</sup>

The SLR test is almost universally positive when a disc is the cause of sciatica, but the test was shown to be negative in up to 85% of individuals experiencing chronic back pain and sciatica in a large sample drawn from a general population.<sup>57</sup> Even among those referred to neurosurgeons and orthopedic surgeons for spine care, the SLR test was negative in 57%.<sup>44</sup> Myelography or MR imaging demonstrates a positive finding only in 65%<sup>44</sup> to 75%,<sup>5</sup> but a significant percentage of those positive myelograms and MR images are positive only coincidentally<sup>37</sup> and not etiologically.

Magnetic resonance neurography<sup>20,21,33</sup> and interventional MR imaging provide greatly enhanced diagnostic capability for the evaluation of entrapment<sup>22</sup> of the proximal sciatic nerve and its precedent neural elements.<sup>19,49</sup> In this study we assessed the outcomes of both surgical and percutaneous invasive treatments based on the results of these new diagnostic techniques.

In addition, a major focus of this study was to address the null hypothesis that nerve-based imaging is unnecessary or unhelpful in the diagnosis and treatment of sciatica. Western medicine is based on objective observation (for example, the physical examination) leading to a diagnosis, and it is well established that imaging is a useful adjunct to the physical examination to extend the physician's capabilities for inspection of the patient and of the potential disease(s) at hand; however, despite the availability of MR neurography for more than 10 years and the publication of numerous reports and supportive outcome studies,<sup>15,23,36</sup> nerve-based imaging is typically omitted by specialist physicians caring for patients with possible sciatic entrapments.

To disprove the null hypothesis, it will be necessary to show that MR neurography does reveal diagnostic findings that are not provided by the physical examination or electrodiagnostic studies and that the findings may affect treatment planning or evaluation and treatment outcomes in significant numbers of patients.

One common cause of pelvic sciatic entrapments may be piriformis muscle syndrome. It has been considered that no objective test for the existence of this condition, no reliable effective treatment, and no reasonable pathophysiology to support its existence exist.<sup>58</sup> Our project included specific elements of data collection intended to address these three principal objections to this diagnosis.

## Clinical Material and Methods

### Patient Selection

Two hundred thirty-nine consecutive patients experiencing leg pain in the distribution of the sciatic nerve and in whom a diagnosis could not be established or in whom lumbar spine surgery did not relieve pain were prospectively entered into this trial. The patients were assessed in the University of California at Los Angeles Comprehensive Spine Program or the Institute for Nerve Medicine in Santa Monica, California (Table 1).

### Diagnostic Assessment

All patients underwent a detailed neurological examination, and all previous diagnostic and treatment data were

TABLE 1  
Summary of demographic characteristics of 239 patients

Characteristic	Value
no. of patients in study	239
sex	
male	102
female	137
age (yrs)	
min	17
max	84
mean	49
prior spine op (%) <sup>*</sup>	46
prior piriformis diagnosis (%) <sup>†</sup>	29

<sup>\*</sup> Indicates percentage of patients in whom previous spine surgery failed for the same symptoms.

<sup>†</sup> Indicates percentage of patients in whom a diagnosis of piriformis syndrome had been proposed prior to referral in this study.

thoroughly reviewed. Patients without adequate lumbar spine imaging data obtained within the past 12 months underwent updated spinal radiography and MR imaging. Patients in whom MR imaging could not provide adequate spinal canal assessment due to the presence of extensive implanted metal instrumentation or implanted electronic stimulators or morphine pumps underwent CT scanning and CT myelography. When a spinal lesion was identified that could cause the presenting symptoms, patients were referred for fluoroscopically guided facet joint blocks, nerve root foraminal blocks, or anesthetic disc injections directed at the spinal lesion. Injections were considered diagnostic when they produced pain relief in patients in whom there had been no response to similar injections in other locations.

**Neurography Imaging Collection.** When a diagnosis could not be established by inspecting routine spine imaging, patients were referred for lumbar and pelvic soft-tissue MR imaging and MR neurography evaluation.<sup>21,33</sup> The FSE images were obtained in 1.5-tesla imagers (GE Medical Systems, Milwaukee, WI, and Siemens, Malvern, WI) by using chemical shift selection for fat suppression. Gradients were 10 millitesla/m. In each case, the magnet was reshimmed with the patient in position before commencing data acquisition. Commercially available phased array coils (typically the GE and Siemens Torso array) were used to enhance signal-to-noise performance. For cross-sectional images we used echo train length 4 to optimize spatial resolution, but echo train length 8 was used for longitudinal nerve images. The field of view was minimized for each study. In all patient studies, T<sub>1</sub>-weighted spin echo and FSE images were collected. For the FSE images, echo time was 95 to 110 msec, time to repeat was 4 to 5000 msec, number of excitations was 2 to 4, and resolution was 256 × 256 to 512 × 512. Slice thickness was 3 mm with 0 mm spacing.

Acquisition of T<sub>1</sub>-weighted axial images was followed by T<sub>2</sub>-weighted fat-suppressed images in the axial, coronal, and nerve-oriented planes (parallel or perpendicular to major nerve courses at the point of evaluation). Images were then subjected to multiplanar reformat postprocessing in a Vitrea (Vital Images, Inc., Plymouth, MN) or Voxar (Voxar, Inc., Framingham, MA) workstation to provide continuous longitudinal nerve images. Calculation of the volume of the piriformis muscles was also completed using Vitrea workstation software.

**Diagnostic Strategy for Piriformis Syndrome.** Results of these imaging evaluations combined with those of physical examinations were used as indications either for fluoroscopically guided diagnostic spinal injections (facet joint, foramina, or disc[s]) or for MR imaging–guided injections of muscle or nerve near lumbar soft tissues or in the pelvis.

Patients in whom physical examination findings and medical history were consistent with piriformis syndrome and in whom MR neurography did not rule out piriformis syndrome were considered to have probable piriformis syndrome and were referred for open MR imaging–guided piriformis muscle injection. Real-time open MR imaging ensured that all injections were delivered into the piriformis muscle and that any leakage of injectate from the piriformis muscle could be documented.

As a methodological point, it was known that if the diagnosis were only accepted for patients in whom the response to injection was good, then the treatment response in patients with the diagnosis would be 100%. We considered it possible and likely that some patients with piriformis syndrome would not exhibit a response to injection. There was no information available at the outset as to which imaging findings should be considered diagnostic.

Cases in which response to injection was also consistent with the diagnostic criteria were considered to have “confirmed muscle-based piriformis syndrome.” This group might, however, include patients with local but indirect response to mechanical disturbance and to Marcaine or to steroid agent injection. When good-to-excellent surgery-related outcome persisted more than 6 months, however, a subgroup of surgically confirmed, muscle-based piriformis syndrome was created.

These subcategories were considered useful for this study because the objectives were to confirm the validity of the diagnosis itself and to use the diagnosis as a basis for analyzing the utility of various diagnostic evaluations.

### *Diagnosis-Based Treatment*

Treatment based on the resulting diagnoses included spinal surgery, nerve or muscle surgery, percutaneous interventions, or noninterventional management.

**Open MR Imaging–Guided Injections.** When a diagnosis of muscle-based piriformis syndrome was suspected, open MR imaging–guided injections were performed in a Siemens 0.25-tesla imager; a 22-gauge, 15-cm titanium Lufkin needle (EZ-EM, Westbury, NY) was used to inject 10 ml of 0.5% Marcaine and 1 ml of celestone into the piriformis muscle. Because of the large volume of Marcaine necessary, all procedures were conducted in an open MR imaging surgicenter setting with available MR imaging–compatible anesthesia and resuscitation equipment. Aspiration was performed after each injection of 2 ml of Marcaine to minimize the risk of respiratory or cardiac compromise due to intravascular injection. The injection was monitored by serial fast–low angle shot imaging requiring 15 to 18 seconds per image acquisition. Images were obtained in sets of three slices and the needle advance was maintained in the center slice of the three-slice set (Fig. 1). The needle was repositioned if the injectate did not spread evenly in the muscle or if any leakage from the muscle was observed. Typically, each procedure in-

involved imaging of the patient 15 to 25 times during a 30-minute procedure. Postinjection T<sub>2</sub>-weighted MR images were obtained to assess the final distribution of injectate in the muscle.

Patients experiencing complete or near-complete and specific relief of symptoms and in whom spinal injections with similar agents had failed to relieve pain were considered to have confirmed muscle-based piriformis syndrome. If the symptoms recurred within 1 week, the patients were referred for piriformis muscle surgery. If the symptoms recurred after 1 week, up to two additional injections were made at intervals of at least 4 weeks. Those in whom lasting relief was still not obtained were also referred for piriformis muscle surgery.

**Surgical Treatment of Pelvic Entrapment of the Sciatic Nerve.** Generally outpatient surgery was performed. A 3-cm incision was made to allow for a minimally invasive transgluteal approach, piriformis muscle resection, neurectomy of the sciatic and posterior femoral cutaneous nerves,<sup>62</sup> and placement of Seprafilm (Genzyme, Cambridge, MA) as an adhesiolytic agent. A similar approach was used in cases involving sciatic entrapments at the level of the ischial tuberosity. Patients were offered the following options: 1) local anesthetic only; 2) epidural anesthesia; 3) intravenous sedation (propofol [Diprivan]) together with local anesthetic; or 4) general anesthesia.

For piriformis surgery, localization of the 3-cm incision was based on locating the superior medial edge of the greater trochanter of the femur (Fig. 2A and B). This was accomplished using skin markers and an anteroposterior hip radiograph, or by using intraoperative MR imaging (Fig. 2), or Fluoro-Nav (Medtronic Sofamor Danek, Memphis, TN) image guidance with the reference frame attached to an Omni table-fixed retractor (Fig. 2D). The position of the piriformis tendon and the sciatic nerve relative to key x-ray landmarks are shown in Fig. 2E to G. Note that the length and orientation of the femoral neck as well as the size of the greater trochanter may vary significantly among individuals (compare Fig. 2B with Fig. 2E).

After opening the gluteal fascia, blunt finger dissection of the gluteal muscles minimizes exposure-induced trauma and helps ensure outpatient management. It also allows for intravenous propofol/local anesthetic intraoperative management for patients who preferred to avoid general anesthesia. Exposure was maintained using a Shadowline retractor system, which is an anterior cervical-type device with a blade/retractor connection that provides good rigidity under strong tension and allows for rapid replacement of blades as the depth of surgery progresses. A set of blades up to 80 mm in length was sufficient for most patients, although occasionally longer Omni blades were required.

The sciatic nerve was avoided by carefully progressing through the muscle layers until the hard, clear pre-piriformis fascia was reached and the dense yellow fat of the muscle fad pad was seen behind it (Fig. 3C and D). The retractor blades were then reset and the fascia opened carefully by using bipolar cautery and Metz scissors. We used an electrodiagnostic system with EMG monitoring of multiple superior gluteal, inferior gluteal, tibial, and peroneal nerve innervated muscles set at 0.5 to 10 mAmp to identify nerves prior to their exposure in the piriformis fat



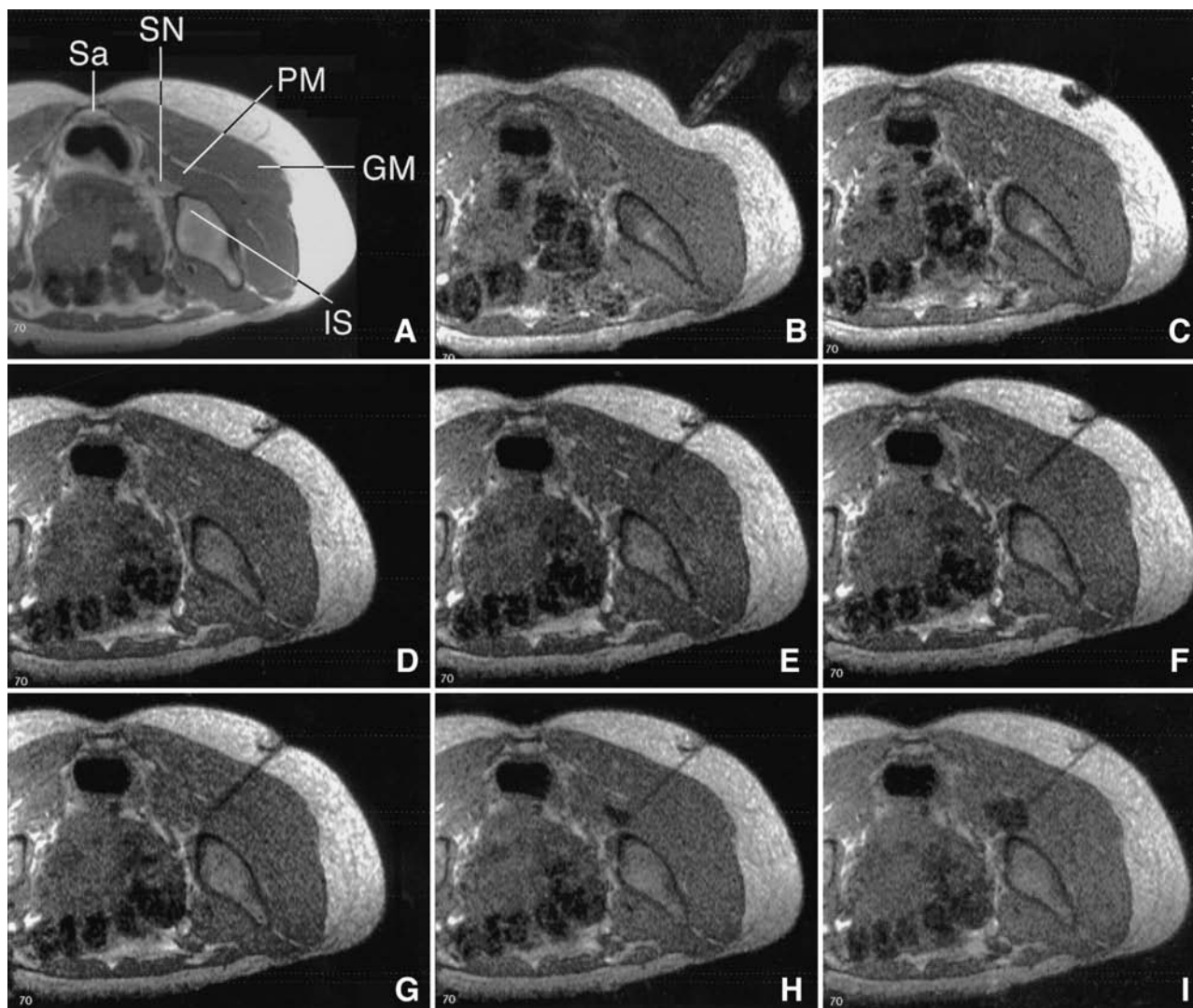


FIG. 1. Open MR imaging-guided piriformis muscle injection. A: A  $T_1$ -weighted image. GM = gluteus maximus, IS = ischium, PM = piriformis muscle, Sa = sacrum, SN = sciatic nerve. B: Physician's finger indicating approach. C: Subcutaneous local anesthetic. D–G: Titanium Lufkin needle advanced into piriformis muscle. H & I: Marcaine injection darkens the muscle (the images in B–I were 14-second, two dimensional fast-low angle shot images.)

pad. When a nerve was not immediately visible, a high milliamperage was used to locate its vicinity, and decreasing milliamperage was then applied as the dissection approached the nerve. In this manner, it was possible to locate and protect, reliably and safely, the sciatic nerve (Fig. 3E), the inferior gluteal nerve, and superior gluteal nerve.

The sciatic nerve was partially mobilized and used, together with the greater trochanter and the sciatic notch, to identify and confirm the borders of the piriformis muscle. Ties were placed around the muscle in two locations (Fig. 4A) so that bipolar cautery and Metz scissors could be used to transect fully the muscle in two locations with complete ongoing hemostasis. Removal of a segment of muscle approximately 2 cm in length helps ensure against readhesion of the separated segments that can occur when a single cut is made. In this procedure the nerve to the pir-

iformis muscle is also generally severed resulting in subsequent atrophy of any remaining components.

The distal lumbosacral plexus, sciatic nerve, and posterior femoral cutaneous nerve then undergo blunt dissection-assisted neuroplasty generally by using DeBakey pickups and a tonsil clamp. Specifically, this entailed separating any abnormal fibrous covering from the nerve so that the nerve can be free and fully mobile at the end of the dissection. In many cases, fibrovascular bands cross or compress the sciatic nerve and can be cut. Gentle dissection technique, liberal use of electrodiagnostic stimulation when nerve locations were in question, and meticulous bipolar cautery hemostasis before cutting any tissue help ensure the safety of the neural tissues.

In some patients an accessory piriformis muscle compressed the more proximal portion of the sciatic nerve, and this was also sectioned and removed. By swinging the

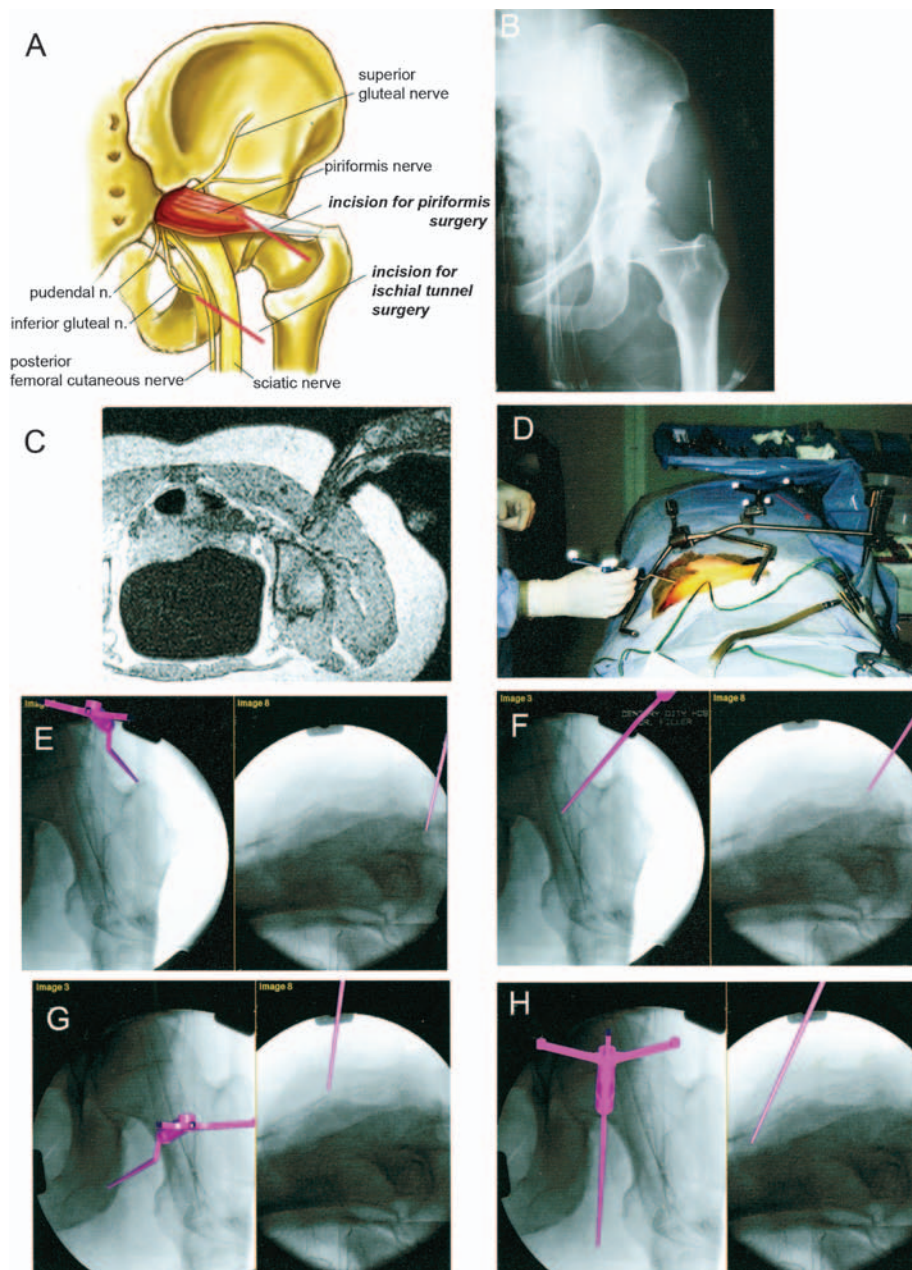


FIG. 2. Localization for the incision and intraoperative orientation. A: Drawing of anatomy of the sciatic notch. The piriformis muscle arises on deep surface of the sacrum, passes through the greater sciatic notch, and inserts on the greater trochanter of the femur. The superior gluteal nerve typically exits above the piriformis muscle in the notch, and the inferior gluteal nerve exits inferior and posterior to the muscle. The posterior femoral cutaneous nerve typically parallels the course of the sciatic nerve. The pudendal nerve also exits the greater sciatic notch, passes over the sacrospinous ligament and then under the sacrotuberous ligament to reenter the pelvis through the lesser sciatic notch. The nerve to the piriformis muscle exits the greater sciatic notch deep to the piriformis muscle. Many of these features are subject to significant individual anatomical variation. Red lines mark the position of the incision for piriformis surgery (*upper line*) and for ischial tunnel surgery (*lower line*), both approximately 3 to 4 cm in length. For piriformis surgery, the lateral inferior end of the incision is over the tip of the greater trochanter and it proceeds medially and superiorly at a 45° angle. This ensures that one of the long retractor blades can be placed just medial to the tip of the trochanter. B: Preoperative radiographic demonstrating localization of the incision. Two 18-gauge needles are taped to the skin, pointing to the presumed position of the superior tip of the greater trochanter. C: Intraoperative image of piriformis surgery performed using open MR imaging guidance in a Siemens 0.25-tesla imager. The surgeon's finger is palpating the sciatic nerve at the level of the ischial spine. The patient is prone. D–H: Fluoro-Nav system and optical guidance images showing the sciatic nerve position. The reference marker is attached to a table-mounted Omni retractor arm, and the surgeon uses a hand-held pointer to identify the sciatic nerve course (D). Anteroposterior and lateral fluoroscopy imaging pairs with computer-generated virtual image of guidance probe superimposed in purple (E–H). Piriformis muscle attachment point on the greater trochanter (E). Sciatic nerve course as it descends below the level of the piriformis muscle (F). Position of the ischial tuberosity at a level where sciatic entrapment often occurs in ischial tunnel syndrome (G). Course of the sciatic nerve as it exits from and descends below the ischial tunnel (H).



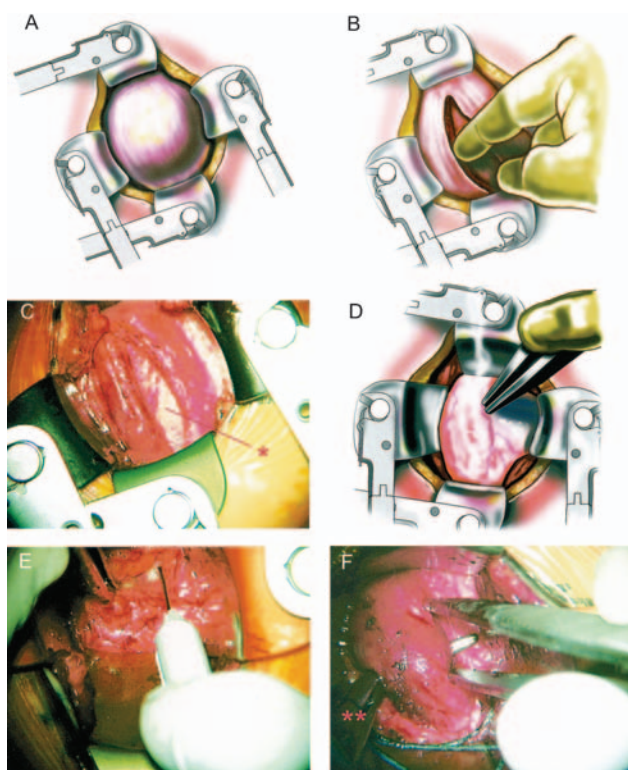


FIG. 3. Transgluteal approach to the piriformis muscle and sciatic nerve. A: Using a Bovie coagulator, the subcutaneous fatty tissue is dissected until the gluteal fascia is reached. This is coagulated along a line by using the bipolar coagulator and incised sharply using Metz scissors. The fascia will be repaired using O-vicryl sutures at the end of the operation. B: Blunt dissection is performed with the finger tip but also by using a tonsil clamp, bipolar, and Metz scissors to progress between sheets of gluteal musculature to approach the prepiriformis fascia. There is no need to cut any gluteal musculature. C: After dissection through 5 to 6 cm of gluteal musculature, the glistening, semitransparent, hard prepiriformis fascia (*asterisk*) is exposed; below it is fatty tissue that will typically herniate when the fascia is incised. D: The prepiriformis fascia is coagulated using bipolar cautery and then cut with Metz scissors. Evaluation with a nerve stimulator will ensure against inadvertent injury to components of the superior or inferior gluteal nerves. E: The first task after entering the prepiriformis fat pad is to use a nerve stimulator with electromyography or manual monitoring to identify and protect the sciatic nerve as it passes inferior to the piriformis muscle. The location of the gluteal nerves should also be identified. F: The margins of the piriformis muscle are then identified and a right-angle clamp is passed below the muscle to pass an O-silk tie.

retractor system, the sciatic nerve can be readily reached from the top of the ischial tuberosity to the top of the sciatic notch, allowing for full mobilization of at least 12 cm of the nerve course. In a small number of cases in which extended access was required, a MetRx system X-tube set (Medtronic Sofamor Danek) was used to extend the range of access further from the original incision. Decompression and muscle resection within the pelvis through the sciatic notch is not recommended routinely because of the higher risk to autonomic fibers in the presacral area.

We administered 4 mg of dexamethasone intravenously

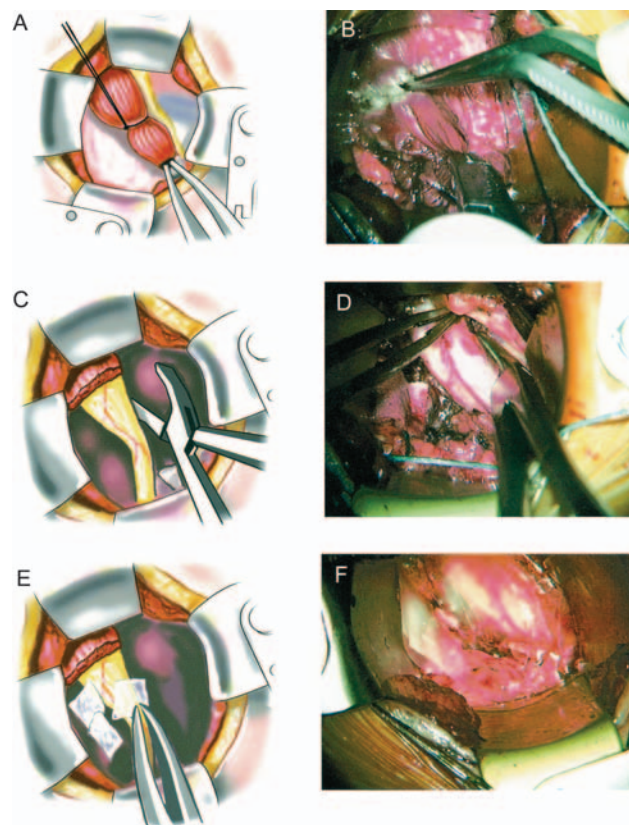


FIG. 4. Piriformis resection and sciatic neuroplasty. A: Two ties are passed around the piriformis muscle and tied—one proximal and one distal. The distal portion near the tendon of attachment is coagulated using bipolar cautery, in layers, and cut in layers with a Metz scissors. B: The distal end, once disconnected, can be grasped with a tonsil clamp and pulled distally while the proximal muscle is incised. This results in complete disconnection and removal of a 2-cm segment of the muscle. The nerve to the piriformis muscle is typically cut in this process as well. C: With the piriformis muscle cut, the full extent of the sciatic nerve in the region is explored. Approximately 6 in of nerve can typically be explored, extending to and through the sciatic notch as well as distally along most of its course above the ischial tunnel. D: A complete neuroplasty can include both the superficial and deep surfaces of the nerve. The posterior femoral cutaneous nerve is also identified and mobilized as it courses just superficial to and parallel with the sciatic nerve. E: Sefrafilim is cut in small squares and placed along all dissected nerve surfaces. A double layer is helpful. F: Adhesion of muscle remnants to the nerve can be further inhibited by lining the cut muscle surfaces with small sheets of Sefrafilim.

at the start of the procedure. Powder-free gloves were used to reduce further the risk of postoperative fibrosis. Only bipolar cautery was used once the gluteal fascia was reached. Meticulous and complete hemostasis was ensured prior to closure. On completion of the neuroplasty, the wound was irrigated copiously with antibiotic irrigation maintained at body temperature in a solution warmer. Sefrafilim pieces were placed in layers on all dissected nerve surfaces as an adhesiolytic agent.

Marcaine (0.5% without epinephrine) was applied to the Sefrafilim and dissected nerves and was instilled in gluteal muscles along the line of the approach. The gluteal fascia was closed using O-vicryl sutures. The skin was

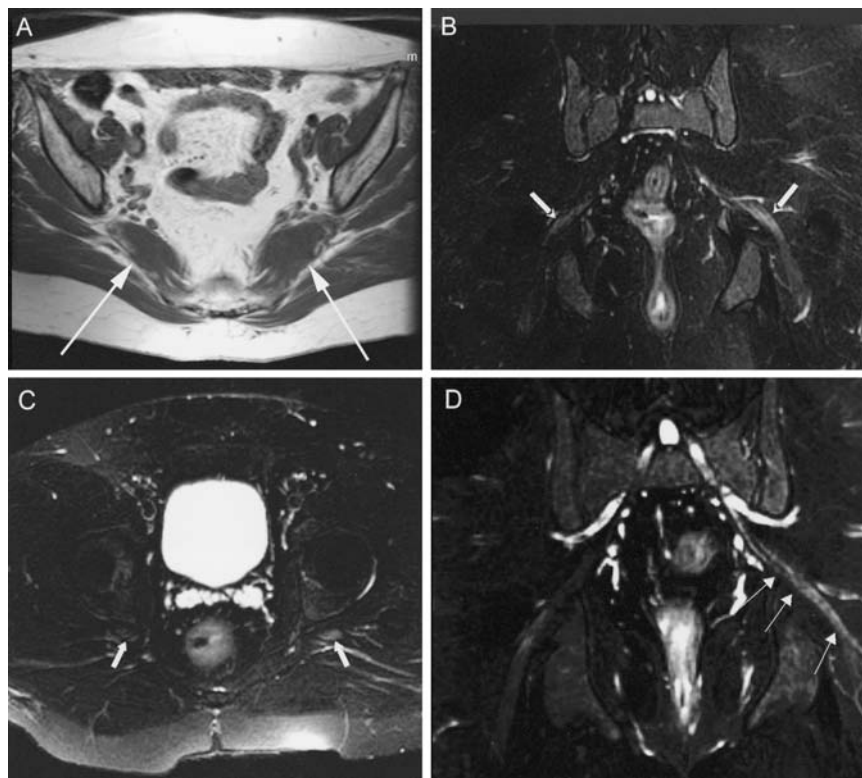


FIG. 5. Magnetic resonance neurography findings in piriformis syndrome. A: Axial T<sub>1</sub>-weighted image of piriformis muscle size asymmetry (arrows indicate piriformis muscles). The left muscle is enlarged. B and C: Coronal and axial images of the pelvis. Arrows indicate sciatic nerves. The left nerve exhibited hyperintensity. D: Curved reformatted neurography image demonstrating left sciatic nerve hyperintensity and loss of fascicular detail at the sciatic notch (arrows).

closed using inverted interrupted 3-0 vicryl sutures in the dermal layer and a 4-0 vicryl subcuticular stitch. The wounds were dressed with Steristrips, a small amount of gauze, and clear dressing. No drains were placed. Patients were allowed to ambulate immediately. They were encouraged to avoid sitting for more than 30 minutes without a break for the first 3 weeks postoperatively. Patients experiencing significant muscle spasm or local pain underwent pain management therapy in the facility overnight.

#### Outcome Measures

Outcomes were assessed using a modified ODI questionnaire in parallel with routine clinical follow-up examination and supplementary questionnaires. No outcome measure has been validated for piriformis syndrome because this study was intended to help establish the validity of that diagnosis. The ODI functional outcome scale was selected in place of a visual analog pain scale by analogy with the use of ODI for lumbar spine surgery outcomes.<sup>10,16</sup> A six-point difference was considered clinically relevant for the fundamentally dichotomous question of whether patients improved after this management regimen.

Follow-up duration ranged from 6 months to 6 years. The mean follow-up period was 2 years. Approximately one third of the patients were followed more than 2 years.

Although data were collected during a 6-year period, many patients attended follow up for shorter durations

because they entered the study later. There was no apparent bias in the numbers of patients lost to follow up as stratified by outcome or by entry time in the total span of the study. Most follow-up examinations after 1 year were conducted by telephone interview or mail. Approximately 15% of patients in the study did not respond to mail and phone inquiries (lost to follow up), and this led to decreased follow-up duration.

#### Assessment of Clinical Efficacy of MR Neurography for Diagnosis of Piriformis Syndrome

In patients undergoing MR neurography of the pelvis, the images were obtained in those with sciatica of nondisc origin as an early step in evaluation before a diagnosis was established. The images were evaluated independently by two experienced readers (J.P.V. and A.G.F.). To confirm the objective validity of the subjective image readings, two findings—asymmetry of the piriformis muscle and relative sciatic nerve image intensity at the level of the sciatic notch—were subjected to detailed analysis (Fig. 5). These two findings were analyzed in 44 patients who experienced a good-to-excellent response to treatment after a diagnosis different from piriformis syndrome was established (for example, nerve tumor, sacral fracture, and distal foraminal entrapment) as well as in 39 patients who experienced persistent good-to-excellent outcome after piriformis surgery. All 73 patients underwent pelvis neurography conducted when only a general diagnosis of sciatica had been reached.



TABLE 2

*Final diagnoses after evaluation and treatment in 239 patients*

Diagnosis	% of Patients
piriformis syndrome	67.8
distal foraminal entrapment	6.0
ischial tunnel syndrome	4.7
no diagnosis	4.2
discogenic pain w/ referred leg pain	3.4
pudendal nerve/sacrospinous ligament	3.0
distal sciatic entrapment	2.1
sciatic tumor	1.7
lumbosacral plexus entrapment	1.3
unappreciated lat disc herniation	1.3
nerve root injury due to spinal op	1.3
inadequate spinal root decompression	0.8
lumbar stenosis presenting as sciatica	0.8
sacroiliac joint inflammation	0.8
sacral fracture	0.4
tumor in lumbosacral plexus	0.4

In a sample of patients with muscle asymmetry, all outlines of each piriformis muscle were traced into the Vitrea image analysis system to allow measurement of the actual muscle volumes and shapes. In patients with unilateral muscle spasm shapes should be altered without changes in volume. In other patients volumes will be different because of either hypertrophy or atrophy on a unilateral basis.

A similar process was used to assess the reliability of subjective assessments of nerve image intensity. These were cross-checked in a sample of patients by measuring the mean pixel intensity in the area of the nerve at the index slice and then comparing it with that of surrounding muscle. Comparisons between right and left sides were made for the muscle and nerve measurements.

## Results

### Diagnostic Findings

Diagnoses established using the present methods are

TABLE 3

*Summary of presenting signs and symptoms in patients with piriformis syndrome*

Presentation	Value
buttock & leg pain (%)	100
back pain (%)	
moderate	33.30
severe	9.10
foot or leg weakness	1.23
duration of symptoms	
mode	2 yrs
mean	4.2 yrs
range	1 mo–15 yrs

listed in Table 2. The most common diagnosis was a muscle-based piriformis syndrome (Table 3). Four other types of pelvic sciatic nerve entrapment were also diagnosed and treated. In 14 patients (6.1%) the origin of their symptoms was in the spine (distal foraminal entrapments) but could not be diagnosed using standard methods (Fig. 6).

**Physical Findings in Pelvic Sciatic Entrapment Syndromes.** Patients with sciatic nerve entrapment exhibited symptom patterns and physical examination findings that differed significantly from those in patients with spinal causes for their symptoms. Unlike patients with herniated discs, these patients typically experienced symptoms in all five toes (multiple dermatomes) rather than lateral toes (S-1 radiculopathy) or medial toes (L-5 radiculopathy) as commonly seen in those with herniated lumbar discs. Many patients indicated that the pain extended primarily only as far as the knee, ankle, or heel. Pain was the predominant symptom, whereas actual numbness or weakness was rare. The SLR test was generally negative, but resisted abduction or adduction of the flexed internally rotated thigh usually reproduced the symptoms (Fig. 7). Sciatic notch tenderness or pain at the greater trochanter was usually demonstrated (Tables 3 and 4). Most patients reported that sitting exacerbated their pain and walking relieved it. Trochanteric bursitis responsive to bursa injection

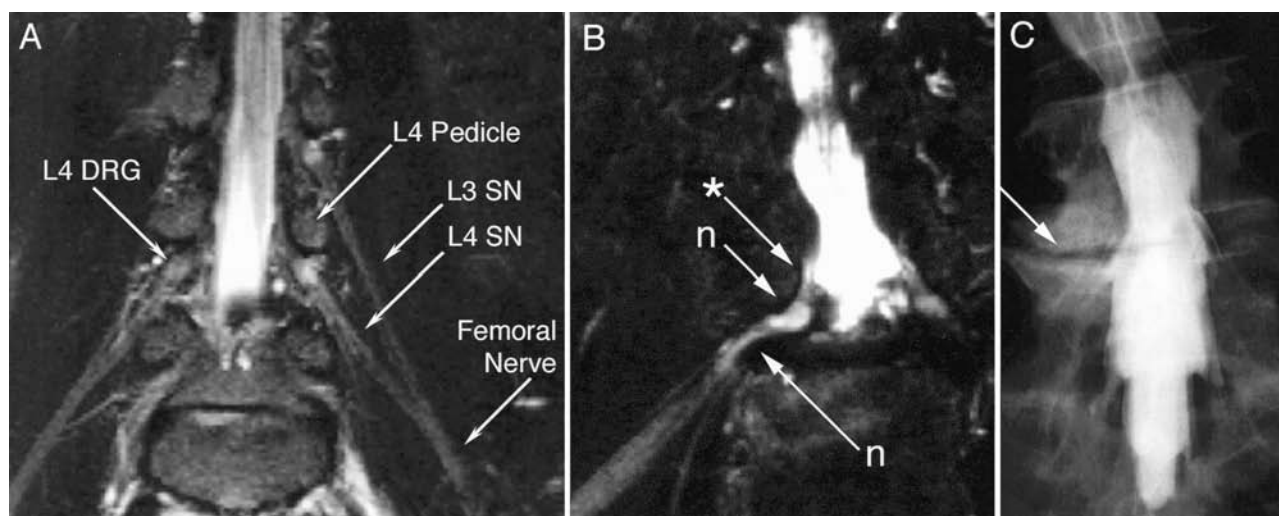


FIG. 6. Lumbar MR neurography for evaluation of distal foraminal lumbar nerve root entrapment. A: Normal linear course of lumbar spinal nerves (SN). B: The L-5 root (asterisk) in a patient with radiculopathy unchanged after two ineffective spine surgeries. The distal root shows focal narrowing and a region of hyperintensity (n). N = nerve. C: Myelogram revealing apparently normal nerve root exit.



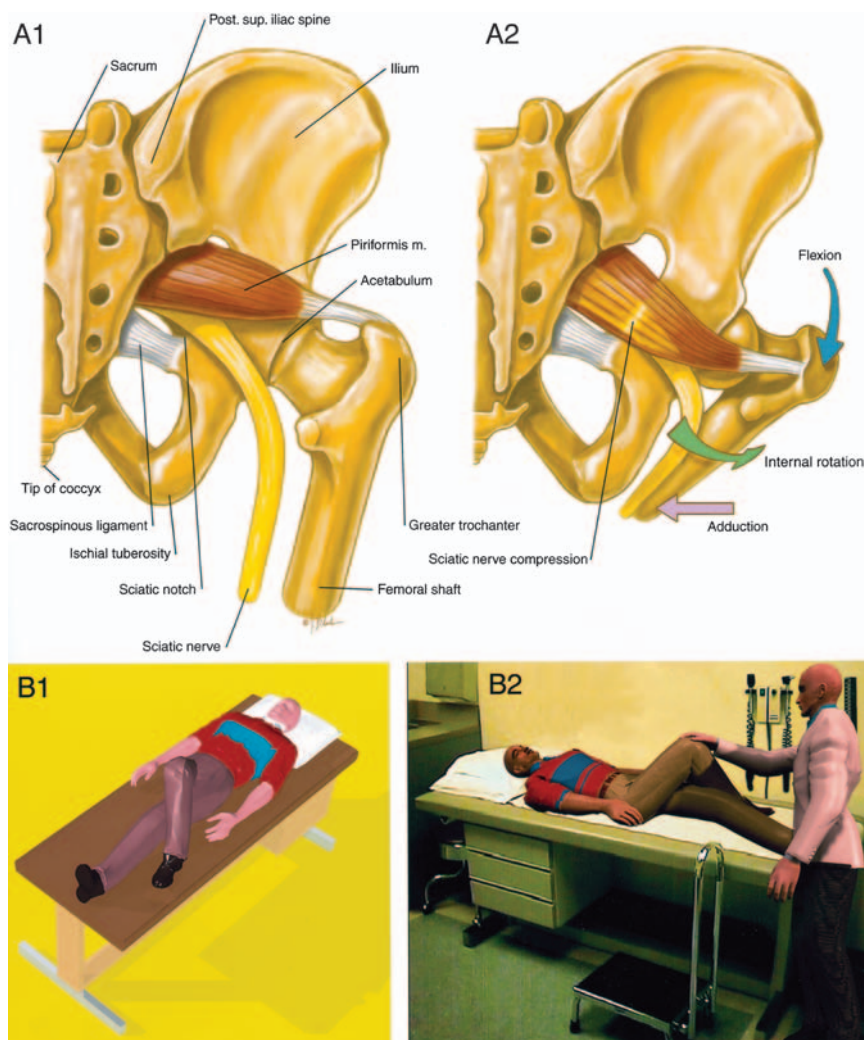


FIG. 7. Anatomy and physical examination for piriformis syndrome during a flexed internally rotated thigh adduction maneuver. A1 and A2: The maneuver pulls the piriformis muscle against the sciatic nerve at the osseous margin of ischium. B1 and B2: The patient's foot is placed lateral to the contralateral knee with resisted adduction against the examiner's hand to reproduce the symptoms. M = muscle; post = posterior; sup = superior.

tion occurred in 7% of patients in whom muscle-based piriformis syndrome was diagnosed.

Four patients suffered associated groin pain in a pudendal nerve distribution. This pain was relieved, as was sciatica, by image-guided injection of the piriformis muscle, or it was relieved selectively by injection near the pudendal nerve at the sacrospinous ligament.

Patients with nerve entrapment at the level of the ischial tuberosity (what we call "ischial tunnel syndrome") exhibited tenderness to palpation at the lateral surface of the ischial tuberosity, which is approximately 3 in below the level of the sciatic notch. Obturator internus pain often associated with pudendal nerve entrapment presents at the medial surface of the ischial tuberosity.

Those with discogenic pain syndromes secondary to annular disc tears experienced referred pain in variable buttock and posterior thigh distributions without specific focal tenderness in the buttock. Percussion over the spinous processes generally reproduced the pain. Upper-buttock and iliac crest pain was generally associated with fa-

cet syndromes or with chronic muscle spasm due to post-fusion flat-back syndrome. In one such patient pain responded to injection at and subsequent neuroplasty of the superior gluteal nerve.

*Neurography for Various Causes of Nondisc Sciatica.* Magnetic resonance neurography proved helpful for correctly identifying those patients in whom lumbar disc surgery had been technically inadequate or incomplete and who needed surgical reexploration for definitive nerve root decompression (Fig. 8A) or in whom there had been unappreciated injury affecting a lumbar or sacral spinal nerve (Fig. 8B and C). This technique also allowed localization of sciatic nerve entrapment whose treatment resulted in relief of RSD (complex regional pain syndrome) (Fig. 8D). Coactive pathophysiology such as hip joint arthritis could be shown to cause sciatica as well (Fig. 8E). Sciatic tumors were also readily identified (Fig. 9) including tumors as small as 2 mm in size.

Magnetic resonance neurography depiction of the exiting spinal roots and nerves, the lumbosacral plexus, and

TABLE 4  
Findings on physical examination in patients  
with piriformis syndrome\*

Finding	% of Cases
sciatic notch tenderness	70.8
FIRT-B or -D	63.0
FIRT-D	58.0
FIRT-B	43.5
positive SLR	40.7

\* FIRT = flexed, internally rotated thigh elicited by abducting (FIRT-B) or adducting (FIRT-D) the knee with the leg in this position.

proximal sciatic nerves reliably identified the lesion in most patients in whom routine modalities (lumbar MR imaging and radiography alone) failed to establish a diagnosis. Useful guidance for surgical planning was provided by imaging because it depicted both areas of nerve abnormality and of tissues surrounding the nerves that contributed to the disorder.

Orientation of image acquisition planes parallel or perpendicular to the nerve course being assessed for diagnosis resulted in accurate determination of local abnormalities in nerve image intensity that reflected the presence of nerve irritation or edema.<sup>13,21</sup>

**Neurography Findings in Patients With Piriformis Syndrome.** Although piriformis muscle hypertrophy has been reported previously as an imaging finding in piriformis syndrome,<sup>35,56</sup> we observed ipsilateral muscle atrophy in some patients as well. Among patients who exhibited a good or excellent response to piriformis surgery, preoperative imaging revealed ipsilateral piriformis muscle hypertrophy in 38.5% and ipsilateral piriformis muscle atrophy in 15%. In some cases, asymmetrical positioning in the imaging system made assessment difficult, but interobserver agreement and cross-confirmation by workstation assessment of geometry showed very high reliability for this finding.

Edema or hyperintensity in the ipsilateral sciatic nerve relative to the contralateral nerve was sometimes difficult to confirm because of magnetic field inhomogeneity and radiofrequency coil geometry; however, this could be determined, agreed on between observers, and confirmed by measurement in 94% of cases. In patients in whom this was found, 88% experienced reproduction of symptoms with abduction or adduction of the flexed, internally rotated thigh.

In patients with sciatica of nondisc origin (no response to disc treatment or no evidence of disc herniation on lumbar MR imaging), the two image findings of piriformis muscle asymmetry and unilateral sciatic nerve hyperintensity at the level of the sciatic notch taken together defined two distinct populations of patients ( $p < 0.01$ ). This pair of image findings showed a specificity of 93% for predicting good-to-excellent outcome from piriformis surgery ( $1 - \text{the false-positive rate}$ ). The two findings had a sensitivity of 64% ( $1 - \text{the false-negative rate}$ ).

The MR neurography finding of sciatic nerve image hyperintensity indicates an important improvement in the utility of imaging for piriformis syndrome. When piriformis muscle asymmetry alone is used as a criterion to

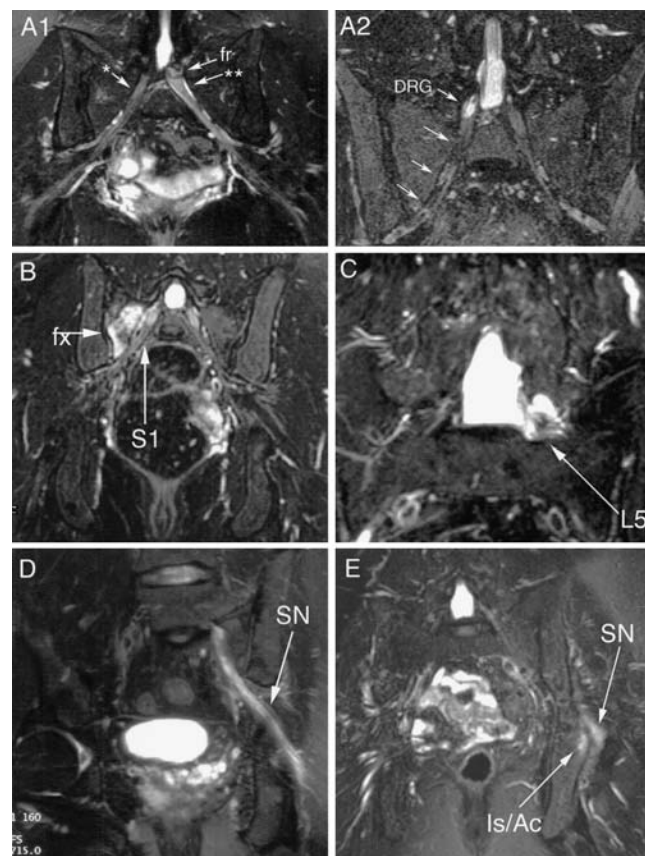


FIG. 8. Magnetic resonance neurography imaging diagnoses of sciatica syndromes in patients with persistent radiculopathy after surgery. A1: Flattening of root (double asterisk) by persistent foraminal disc fragment (fr). A2: Right S-1 dysesthetic pain after microdiscectomy: good decompression with hyperintense dorsal root ganglion (DRG) consistent with intraoperative mechanical trauma; no surgical treatment is recommended. B: Persistent sciatica after a fall with no improvement after discectomy. The image demonstrates inflammation around the nerve (S-1) consistent with a sacral fracture (fx) abutting the foramen. C: Persistent severe left L-5 radiculopathy exacerbated after lumbar spine instrumented fusion, and not relieved by its subsequent removal. The image demonstrates perforation of left L-5 root by the pedicle screw. No further surgical treatment is recommended. D: Sciatic nerve (SN) hyperintensity associated with adhesion to a site of a pelvic fracture in a patient with new-onset RSD. The RSD symptoms resolved after nerve release surgery. E: Inflammation in the ischium adjacent to hip joint arthritis in the acetabulum (Is/Ac) affecting the adjacent transiting sciatic nerve.

identify individuals with piriformis syndrome, the specificity is 66% and the sensitivity is 46%.

**Utility of Open MR Imaging–Guided Injections.** Imaging-guided injection near the sciatic nerve did not relieve symptoms if the injection was made at the incorrect site. Injection in the same individual at both the level of the piriformis muscle and at the level of the ischial tuberosity produced pain relief at only one or the other location (16 of 16 patients receiving injections at two pelvic sciatic sites on the same side). Surgery based on this distinction produced good outcomes at a rate similar to that achieved when administering a single injection. Patients with excel-

TABLE 5

*Symptomatic responses to piriformis anesthetic injection in 162 patients*

Group	No. of Cases (%)	Duration of Relief
I	24 (15)	8 mos–6 yrs, no recurrence
II	13 (8)	2–4 mos w/ lasting relief after 2nd injection
III	60 (37)	2–4 mos w/ recurrence after 2nd injection
IV	39 (24)	1–14 days of relief
V	26 (16)	no improvement

lent outcomes after injection into the piriformis muscle or piriformis surgery saw a mean of 8.5 specialist physicians for their sciatica before this diagnosis was proposed.

#### *Treatment Outcomes*

In patients in whom standard diagnostic modalities indicated an absence of treatment options at the University of California at Los Angeles Comprehensive Spine Center, our additional effort at diagnosis and treatment yielded good or excellent outcomes at 6 months in more than 80% of the total study population.

**Injection Outcomes in Piriformis Patients.** One hundred sixty two patients (68% of the overall 239 patients) in whom the ultimate diagnosis was piriformis syndrome underwent open MR imaging–guided piriformis muscle injections. Results of injection led to assignment to one of five groups (Table 5). Of these patients, permanent and complete relief of their piriformis syndrome was achieved in 23% after one- or two-injection treatments (Groups I and II).

An intermediate group consisting of 37% of these injection-treated patients experienced prolonged relief followed by recurrence (Group III). In many of these patients, when the symptoms recurred their severity had decreased. Some of these patients received periodically additional injection, others continued to defer any further treatment, and some elected to undergo surgery in hope of a definitive resolution of the condition.

Group IV patients who experienced a clear and complete relief of symptoms for a few days followed by complete recurrence typically opted for surgical treatment.

In some patients piriformis syndrome was diagnosed despite an absent response to injection (Group V). These diagnoses were based on imaging, history, and physical examination data. In some of these patients there was a specific temporary exacerbation of symptoms due to the injection, but others experienced only transitory effects or no effect at all in the hours after the injection.

#### *Surgical Outcomes in Patients With Piriformis Syndrome*

Patients in whom injections resulted in a definite diagnosis of muscle-based piriformis syndrome and who elected to undergo surgery (Injection Groups III and IV) formed a homogeneous group in which formal outcomes analysis of surgical treatment could be performed.

In both groups referred for surgery, treatment resulted in 82 initial and 76 long-term good or excellent outcome (Table 6). This was statistically significant in the population size studied ( $p < 0.01$ , chi-square test) compared with

TABLE 6

*Summary of outcomes after piriformis surgery*

Outcome	% of Patients
initial (64 cases)	
excellent	59
good	23
no benefit	17
worse	2
long-term (>2 yrs; 21 cases)	
modified ODI	
excellent	62
good	14
no benefit	24
worse	0

the null hypothesis positing that at least 50% of these patients would have improved even if no treatment had been administered. This null hypothesis was based on results obtained in a large prospective trial<sup>5</sup> in which investigators evaluated nonsurgically managed patients with sciatica, from a population comparable to this study, in whom imaging did not demonstrate relevant nerve root compression.

In three patients (5%) recurrence was observed in the first 2 years. Two underwent reoperation and experienced lasting relief; in the third, recurrence was demonstrated again. Only two of the 64 patients elected to undergo surgery with a local anesthetic alone and both fared well without significant intraoperative discomfort or difficulty walking after surgery. Forty-three patients elected to undergo induction of general anesthesia, and in 19 surgery was performed after intravenous administration of propofol and local anesthetic. There were no differences in outcomes stratified by type of anesthesia, although patients in whom general anesthesia was induced were more likely to stay overnight in the hospital. The mean duration of surgery was approximately 2 hours.

The follow-up period for patients who underwent surgery for piriformis syndrome ranged from 6 months to 6.5 years (mean 2 years). The subset of patients (23 cases) who attended follow up for more than 2 years maintained good or excellent outcomes at greater than 70%.

In those patients who underwent surgery, there was no evidence of increased incidence of anatomical variants affecting the piriformis muscle or sciatic nerve. Although some variants were observed, their incidence was not any greater than that reported for the general population. None of the patients who underwent surgery for piriformis syndrome reported any gait abnormality or other new surgery-related disability. Complications included one wound hematoma in a patient receiving Coumadin and three superficial wound infections that responded to oral antibiotic therapy. Ninety-two percent of patients reported returning to work or to presurgical activity level within 2 weeks postoperatively.

#### *Investigation of Treatment and Diagnostic Exceptions*

Following the main portion of the study, three patients with histories, physical findings, and imaging data consistent with piriformis syndrome, but who did not experience any response to imaging-guided piriformis injection, were



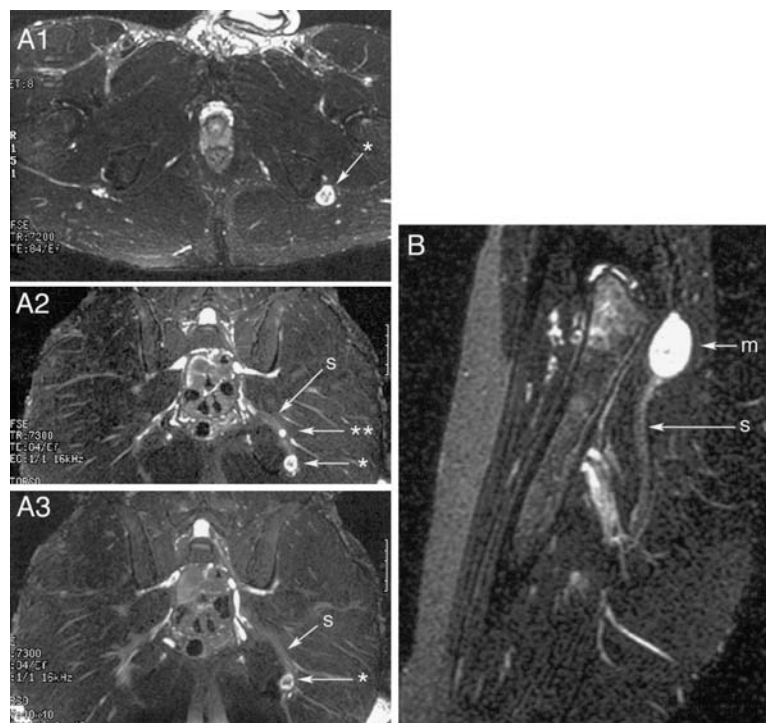


FIG. 9. Sciatic nerve tumors. A1–3: After physical therapy, lumbar discectomy, and piriformis muscle sectioning, all without benefit, initial sciatic imaging revealed schwannomas (*asterisk* and *double asterisk*) in sciatic nerve near the ischial tuberosity. Symptoms resolved after tumor excision. B: Sciatic nerve (s) with mass (m) in a patient with sciatica, positive SLR test, and lumbar spondylosis. Symptoms resolved after tumor excision.

nonetheless referred for resection of the piriformis muscle. Surgery was recommended, the rationale being that no other diagnosis could be made and that some individuals might exhibit an irritative response to injection that mediates the relaxing effect of the Marcaine.

In the first of these patients initial surgery provided no benefit. Postoperative imaging revealed a remnant strand of piriformis muscle adjacent to the sciatic nerve. Repeated operation to excise what proved to be a small accessory piriformis muscle resulted in lasting relief of symptoms. In the second patient, resection of both the main body of the piriformis muscle and a small adjacent accessory muscle resulted in good relief of preoperative sciatic symptoms.

In the third patient reimaging involving an improved nerve cross-section MR neurography protocol revealed that the sciatic nerve was actually split by a small filament of muscle passing through the nerve (Fig. 10). Resection of the muscle filament and of the piriformis muscle in combination with sciatic nerve neuroplasty resulted in significant improvement.

## Discussion

### Role of Diagnostic Nerve Imaging

*Establishment of the Diagnostic Impact of Anatomical Nerve Imaging.* An essential aspect of this study is the application of nerve-based imaging directed at the relevant nerves beyond the level of proximal neural foramen.

The scientific basis for MR neurography has been described,<sup>21,33</sup> and this modality has been submitted to rigor-

ous technical and outcomes evaluation.<sup>11,12,29,36</sup> The context of the outcomes research for neurography is provided by the basic science<sup>14,31</sup> and detailed clinical work<sup>15,34,36</sup> pertaining mostly to median nerve entrapment at the carpal tunnel. This work has been the basis for increasingly widespread acceptance of the modality in the radiological,<sup>1,2</sup> neurological,<sup>23,29</sup> and neurosurgical<sup>15,30,53</sup> literature.

Because diagnostic MR imaging is included in the evaluation, anatomical data are produced that do not fit the simple model of a positive or negative result of a test. The anatomical data produced by routine lumbar MR imaging yield numerous findings that are potentially either false-positive or “valid but irrelevant” depending on the terminology applied.<sup>9,38,59</sup> These data are nonetheless very useful because they tend to produce a finite number of candidate etiological diagnoses that can then be evaluated by comparison with physical examination findings or by direct evaluation with imaging-guided injection. This is particularly relevant when effective surgical therapies can be performed if an anatomical etiological diagnosis can be confirmed by injections.

In this study MR neurography has been relied on, in part, for its purely anatomical value—for example, in identifying nerve tumors, distal foraminal impingements, perineural bone fractures, and other unusual anatomical lesions. The diagnosis of piriformis syndrome could then be established by physical examination and injection when no other etiological finding could be identified on the imaging study.

*Magnetic Resonance Neurography in Piriformis Syndrome.* After having established the diagnosis and undertaken the treatment, it became possible at the close of the

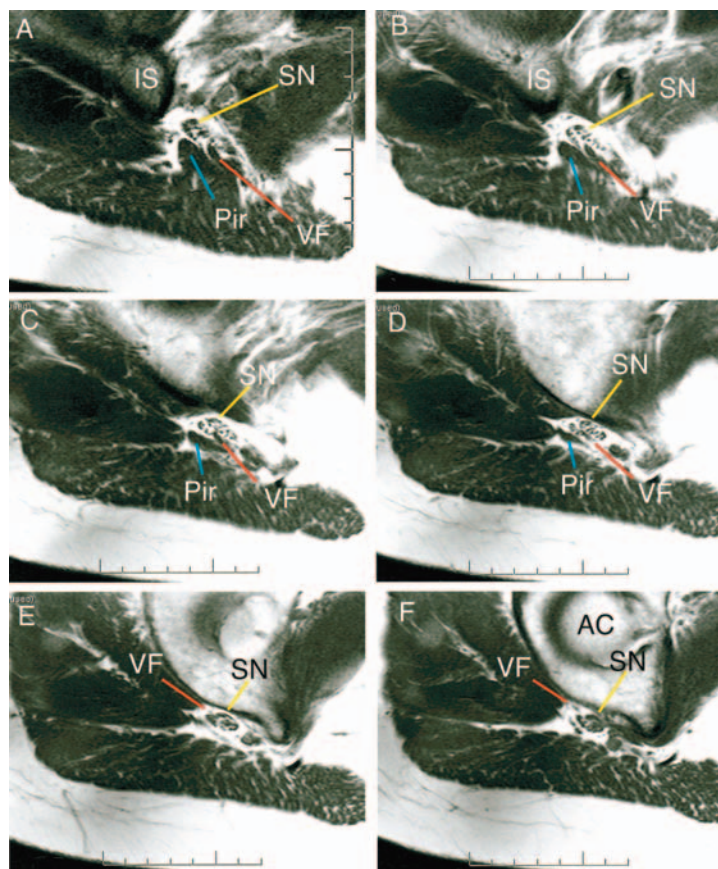


FIG. 10. Variant sciatic anatomy: muscle passing through nerve. This series of axial T<sub>1</sub>-weighted images of the right pelvis progress at 3-mm intervals from the midlevel of the sciatic notch to the level of the acetabulum (A–F). The images document the passage of a variant muscle filament (VF) through the sciatic nerve (SN) at the sciatic notch. AC = acetabulum; IS = ischium; Pir = piriformis muscle.

study to identify two matched groups of patients, all with sciatica unrelated to lumbar disc herniation. One group responded to sectioning of the piriformis muscle after a specific diagnosis of piriformis syndrome had been established according to study protocol; the second group responded to surgical treatment of a structure other than the piriformis muscle after specific diagnosis of some condition other than piriformis syndrome. Data obtained in these two populations could form the basis for investigating the diagnostic efficacy of MR neurography in the diagnosis of piriformis syndrome. This approach showed unequivocally the diagnostic ability of MR neurography for demonstrating unilateral hyperintensity of the sciatic nerve at the sciatic notch.

The relatively high specificity of this finding indicates that image-based nerve hyperintensity at this location indicates clinically relevant nerve irritation. Its sensitivity of 64% undercores that either the syndrome produces a relatively low profile of image-based abnormalities or that the imaging method could be improved.

We followed an imaging strategy available at the inception of the study in 1996. Subsequently others have reported an updated imaging protocol involving oblique image planes and “nerve perpendicular” image acquisition planes that may provide greater sensitivity;<sup>49</sup> however, a new prospective trial is needed to determine whether the present

technique’s high specificity is maintained and whether its sensitivity is indeed increased.

Nonetheless, this study makes clear that MR imaging without MR neurography is not adequate because the former is unable to diagnose the lesion in many patients in whom there are identifiable and treatable abnormalities. The importance of imaging the sciatic nerve in the evaluation of sciatica of nondisc origin cannot be overemphasized. There seems to be no reasonable clinical basis for intentionally choosing not to image this nerve in this situation.

**Class A Imaging Efficacy Study.** We designed the study to meet the criteria of a Class A quality imaging efficacy study for diagnostic accuracy according to guidelines established by the American College of Physicians.<sup>40,41</sup> High-quality studies of imaging efficacy are different from those based on treatments because they assess the ability to predict the outcomes of treatment and can be completed before treatment is commenced. For this reason, appropriate group matching rather than randomization is the critical aspect of study quality.

When a gold-standard diagnostic method exists, both the gold standard and the new diagnostic technique can be applied to the same individuals to establish the best predicted outcomes, rather than relying on effectively identical groups, assigned at random, with each patient receiving one of the two treatments. In this case, however, there

is no existing accepted predictive method of diagnosing piriformis syndrome (that is, no gold standard), and the only definitive diagnosis known is based on outcome after surgery. Therefore, the appropriate question concerns the efficacy of a test or pair of tests in predicting this diagnostic outcome compared with the findings for that pair of tests in matched individuals in whom this diagnosis definitely does not exist.

The relevant portion of the guideline statement is as follows: "For diagnostic accuracy and effect, methodological quality was rated as A if the study had more than 35 patients with and more than 35 patients without the pathological abnormality in question, drawn from a clinically relevant sample whose clinical symptoms were completely described, whose diagnoses were defined by an appropriate reference standard, and whose magnetic resonance images were technically of high quality and were evaluated independently of the reference diagnosis."<sup>40</sup>

The results reported in this study, together with this position on methodology from the American College of Physicians, constitute an absolute and definitive indication for the use of MR neurography in patients with sciatica in whom an obvious spinal origin for this condition is absent.

#### *Open MR Imaging Reduces Uncertainty by Improving the Accuracy of Injections*

The role of highly accurate imaging-guided injection in the pelvis is critical. A blind or fluoroscopically guided needle placement is unlikely to enter reliably the 1- to 2-cm profile of the piriformis muscle at a depth of 8 to 12 cm below the skin surface. Poor accuracy of injection in the piriformis muscle is responsible for confusion about the diagnosis of this condition.

Open MR imaging evaluation of blind transvaginal piriformis injection technique conducted in the design phase of this study revealed that these injections do not reliably reach the piriformis muscle. A transvaginal injection technique does permit the accomplishment of pain relief in patients with symptoms due to the obturator internus or other pelvic floor muscles but is difficult to interpret diagnostically as a guide to subsequent treatment planning.

Use of EMG and fluoroscopy after injecting dye into the muscle<sup>25</sup> can identify the piriformis muscle and confirm the accuracy of the injection, but it does little to mitigate the risk of nerve or bowel injury. This method may also cause unacceptable pain in patients with significant piriformis muscle pain. Ultrasonography provides a very low level of target reliability and few means of confirming the ultimate distribution of the injectate.

Open MR or CT imaging guidance nearly eliminates the risk of penetrating the nerve<sup>18,51</sup> or bowel with the needle, and it allows for documentation of the selective presence of the injectate within the piriformis muscle. Because entrapment of the sciatic nerve near, but not involving, the piriformis muscle requires a different surgical plan, it is important to ensure that only the piriformis muscle receives the injectate.

Radiographic exposure to the unshielded pelvis during a procedure involving CT scanning guidance is a significant concern. Typically, we obtained 15 to 25 imaging series during our open MR imaging-guided injections. For

CT guidance as few as 10 series proved acceptable, but this can be equivalent in dosage exposure to nearly 500 chest radiographs. Because modern CT scanners vary dose with tissue density and body part diameter, the pelvis typically receives the maximum radiation output. In radiological guidance, the relative tolerance to x-ray exposure of various body parts is distinguished and direct unshielded pelvic irradiation is of maximal concern. Therefore CT scanning guidance may not be safe or appropriate given the availability and superiority of open MR imaging guidance for these procedures, particularly when it is locally available for a given clinical population. As in our study, only patients with implanted medical devices contraindicating MR imaging and who provide specific consent regarding knowledge of radiation risk should undergo CT scanning guidance.

There has been a report in which the authors have suggested that injection near the sciatic nerve will produce pain relief whether its origin is in the disc, facet joints, muscles, or any other location.<sup>50</sup> These findings are specifically refuted by the results of our study. Because those injections were conducted without image guidance, the origin of the pain cannot be known. In any case, the imaging-guided injections in this report were completely documented both with regard to location of the needle and distribution of the anesthetic agent. In this setting injections clearly distinguished between different types of sciatic lesions and also distinguished sciatic from spinal pathological entities. One of our patients received two unguided piriformis injections from the lead author of that study (R.B.N.), both with no benefit, yet permanent pain relief was achieved after a single open MR imaging-guided injection of the piriformis muscle.

#### *Minimally Invasive Piriformis Surgery*

Redesign of the surgical strategy for pelvic entrapment of the sciatic nerve to produce a well-tolerated outpatient procedure was an important adjunct to the additional diagnostic evaluations. Older surgical approaches for piriformis syndrome, which involve either detaching the entire gluteal muscle mass<sup>42,58</sup> from the pelvis or which involve the large lateral hip incision used for hip replacement,<sup>46,61</sup> do not seem warranted and should be replaced with limited, targeted muscle-splitting, nondestructive approaches such as the method described in this paper. There is no need to provide the extensive nerve exposure required for intraoperative nerve action potentials<sup>58</sup> when treating a pain syndrome in which there is no evidence of significant reduction in the number of transmitted action potentials.

Our surgical technique follows the concept of Freiberg<sup>26</sup> and Mizuguchi,<sup>48</sup> but it involves modern surgical technology to reduce further the size of and morbidity associated with the incision. This minimally invasive transgluteal approach yielded good outcomes, short recovery time, and good level of comfort for the patients, and it seems appropriate for the treatment of a painful neuropathy.

Use of an incision many times larger than is actually required is only likely to produce more pain than that with which the patient presents when initially seeking treatment. Most patients should be fully ambulatory within 24 hours if not immediately postoperatively. Techniques that only allow ambulation on crutches for weeks and months



## Sciatica of nondisc origin

after surgery should be considered no more acceptable for piriformis surgery<sup>55</sup> than they are for lumbar discectomy.

### *Pathophysiology of Piriformis Syndrome and Basis for Treatment*

**Muscle Spasm Causes Nerve Compression.** One longstanding objection to the validity of piriformis syndrome as a clinical diagnosis has been the unproven assertion that muscle spasm alone cannot produce nerve compression. The results of this study definitively disprove that assertion.

The finding of permanent relief of chronic piriformis pain after one or two muscle-targeting Marcaine injections in 23% of these patients strongly indicates that chronic muscle spasm plays an important role in the origin of this condition in a substantial number of such patients. Similar results have been reported by others.<sup>17,24</sup> Because of its anesthetic effect on the motor nerve, Marcaine paralyzes the muscle temporarily; however, it also produces a longer-acting neuromuscular junction toxicity.<sup>4,8</sup> The prolonged relief, well beyond the half-life of the drug in the tissue, indicates either a prominent role for the toxic effect or the potential of the period of paralysis to break a well-established cycle of chronic muscle spasm. The occurrence of permanent relief can only be explained by an effect that causes cessation of muscle spasm.

The failure of injection to lead to lasting relief in the majority of these patients, however, may well relate to the adhesions of the sciatic nerve to surrounding tissue and to the piriformis muscle observed in this study and discussed from an etiologic point of view in other reports.<sup>7,54,55</sup>

The pathophysiology of chronic muscle-based nerve compression has been explored by Machleder and colleagues<sup>45</sup> in their work on the anterior scalene muscle in thoracic outlet syndrome. The scalene muscle undergoes a transition from fast-twitch glycolytic histology to slow-twitch oxidative muscle fiber type as it becomes entrained in a chronic pattern of increased muscle tone. Relaxation of the anterior scalene muscle with botulinum toxin relieves the nerve compression.<sup>39</sup> A similar process may occur with the piriformis muscle.

Similar to the relationship of the nerve to the anterior scalene muscle, the muscular nerve branch is positioned in relation to the piriformis muscle<sup>3</sup> such that it may be irritated along with the sciatic nerve when exogenous stimuli initiate the increased tone. The constant presence of abnormally stiff impacting muscle at a site where the sciatic nerve normally glides over the sciatic notch edge of the ischium appears to be the proximate cause of the sciatic neuropathy. In some cases, local "autocompression" of the nerve to the piriformis muscle appears to have led to weakening, atrophy, and shortening of the muscle which causes nerve compression relatively resistant to relief by muscle injection.

Mechanical and chemical irritation of the sciatic nerve caused by the abnormally functioning piriformis muscle is perceived by local *nervi nervorum* and this causes nerve pain at the site of compression. Distortion of normal sciatic signal conduction through the area causes the radiating sciatica pain.

Regional sensitization due to local injury, trauma, or strain may cause the patient to notice preexisting low-level symptoms. The response to injection, however, indi-

cates that altered tone in the piriformis muscle is a common pathophysiological mediator.

**Back Pain and Piriformis Syndrome.** The incidence of back pain (42%) in patients with piriformis syndrome indicates an etiological relationship. This is reinforced by the inclusion of two patients in whom acute piriformis syndrome developed after lumbar spine fusion, which was then resolved by piriformis injection. To explain this relationship, we propose a piriformis amplifier theory. In essence, the piriformis muscle is structurally and neurologically homologous with other hypaxial muscles such as the psoas. When low-lumbar spinal lesions lead to back muscle spasm causing back pain, the piriformis muscle may develop increased tone as well. Unlike other back muscles, however, the piriformis muscle crosses the sciatic nerve over the hard edge of the ischium at the sciatic notch. When the piriformis muscle goes into a state of sustained increased muscle tone, it therefore produces not only local muscle pain, but sciatica as well, thus "amplifying" its pain output much like the function of an electronic amplifier.

**Basis for Treatment.** Because the injections relieved the syndrome by relaxing the piriformis muscle, disconnection and resection of the piriformis muscle appear to be indicated in patients requiring surgery. Use of the minimal access approach may explain the complete absence of gait dysfunction in this group of patient at all stages during follow up. The resection removes the muscle when chronic spasm cannot be relieved by injection, when hypertrophy leads to crowding of the greater sciatic foramen, and when atrophy leads to a tight band of shortened muscle. Nerve element neuroplasty in the region—distal lumbosacral plexus, sciatic nerve, posterior femoral cutaneous, and superior and inferior gluteal nerves—further ensures an optimal outcome because intraoperative findings often included the presence of adhesions affecting these nerves.

### *Does Piriformis Syndrome Exist?*

Successful diagnosis and treatment of patients with sciatica in whom routine lumbar disc herniations are absent is important because hundreds of thousands of patients are affected each year.

In a previous study,<sup>44</sup> patients with disabling sciatica and no abnormal findings on myelography were shown to fare poorly with either spine surgery or nonspecific conservative management compared with those in whom myelography was positive and who were managed either conservatively or surgically. The authors of that study concluded that their diagnostic methodology was inadequate to plan the management of this group that represented 35% of all patients with sciatica referred to their clinic. The authors of that prominent multicenter study did not consider piriformis syndrome in their evaluations.

In the present study we evaluated a similar group of patients and used methods that greatly reduced the number of untreatable patients. One of the necessary consequences of this study is that clinicians must accept piriformis syndrome as a real diagnosis with a specific history, physical findings, imaging characteristics, diagnostic methodology, and treatment. This syndrome is not even mentioned once in most current neurosurgical textbooks, and this does a disservice to many thousands of patients who should benefit from its correct treatment every year.

The true incidence of piriformis syndrome is not clear at this time. Lacking agreement even on the existence of the diagnosis and on how to establish the diagnosis if it does exist, epidemiological work has been scarce; however, there is a reasonable inference to be made from the fact that of 1.5 million patients with sciatica severe enough to require MR imaging, only 200,000 prove to have a treatable herniated disc. One interpretation of the results obtained in our study population is that piriformis syndrome may be as common as herniated discs in the cause of sciatica. The typical absence of a positive SLR sign, the presence of multidermatomal pain not extending to the toes, and the negative lumbar MR imaging may account for the low rate of referral of these patients to neurosurgeons and orthopedic spine specialists. The low rate of referral and frequent failure to recognize the diagnosis, however, should not be mistaken for evidence of a low incidence in the population.

### Conclusions

In this study we demonstrated that piriformis muscle syndrome can be accurately diagnosed and treated; additionally, it is the most common cause of persistent sciatica in patients in whom a proper diagnosis could not be established and in whom treatment by the routine spine-centered approach failed for this representative group of patients. A rational and reliable diagnostic and management approach including MR neurography and appropriate imaging-guided injection techniques is capable of establishing the correct diagnosis and guiding management for both pelvic sciatic entrapment and nonstandard lumbar entrapment.

Because an accurate diagnosis is not established in more than 1 million patients with severe sciatica (80% of the total affected population) each year when using the reference standard diagnostic paradigm, our new technologies and the expanded diagnostic criteria merit careful consideration by those primary and specialist physicians charged with the evaluation and management of these patients.

### References

1. Aagaard BD, Maravilla KR, Kliot M: Magnetic resonance neurography: magnetic resonance imaging of peripheral nerves. *Neuroimaging Clin N Am* 11:131–146, 2001
2. Aagaard BD, Maravilla KR, Kliot M: MR neurography MR imaging of peripheral nerves. *Magn Reson Imaging Clin N Am* 6:179–194, 1998 (Erratum *Magn Reson Imaging Clin N Am* 6:May 1998)
3. Akita K, Sakamoto H, Sato T: Arrangement and innervation of the glutei medius and minimus and the piriformis: a morphological analysis. *Anat Rec* 238:125–130, 1994
4. Akiyama C, Kobayashi S, Nonaka I: Comparison of behavior in muscle fiber regeneration after bupivacaine hydrochloride- and acid anhydride-induced myonecrosis. *Acta Neuropathol (Berl)* 83:584–589, 1992
5. Alaranta H, Hurme M, Einola S, Falck B, Kallio U, Knuts LR, et al: A prospective study of patients with sciatica. A comparison between conservatively treated patients and patients who have undergone operation. Part II: Results after one year follow-up. *Spine* 15:1345–1349, 1990
6. American Association of Neurological Surgeons: **National Neurosurgical Statistics: 1999 Procedural Statistics**. Rolling Meadows, IL: American Association of Neurological Surgeons, 1999
7. Benson ER, Schutzer SF: Posttraumatic piriformis syndrome: diagnosis and results of operative treatment. *J Bone Joint Surg Am* 81:941–949, 1999
8. Billington L, Carlson BM: The recovery of long-term denervated rat muscles after Marcaine treatment and grafting. *J Neurol Sci* 144:147–155, 1996
9. Boden SD, Davis DO, Dina TS, Patronas NJ, Wiesel SW: Abnormal magnetic-resonance scans of the lumbar spine in asymptomatic subjects. A prospective investigation. *J Bone Joint Surg Am* 72:403–408, 1990
10. Bombardier C: Outcome assessments in the evaluation of treatment of spinal disorders: summary and general recommendations. *Spine* 25:3100–3103, 2000
11. Britz GW, Haynor DR, Kuntz C, Goodkin R, Gitter A, Kliot M: Carpal tunnel syndrome: correlation of magnetic resonance imaging, clinical, electrodiagnostic, and intraoperative findings. *Neurosurgery* 37:1097–1103, 1995
12. Britz GW, Haynor DR, Kuntz C, Goodkin R, Gitter A, Maravilla K, et al: Ulnar nerve entrapment at the elbow: correlation of magnetic resonance imaging, clinical, electrodiagnostic, and intraoperative findings. *Neurosurgery* 38:458–465, 1996
13. Chappell KE, Robson MD, Stonebridge-Foster A, Glover A, Allsop JM, Williams AD, et al: Magic angle effects in MR neurography. *AJNR* 25:431–440, 2004
14. Cudlip SA, Howe FA, Clifton A, Schwartz MS, Bell BA: Magnetic resonance neurography studies of the median nerve before and after carpal tunnel decompression. *J Neurosurg* 96:1046–1051, 2002
15. Cudlip SA, Howe FA, Griffiths JR, Bell BA: Magnetic resonance neurography of peripheral nerve following experimental crush injury, and correlation with functional deficit. *J Neurosurg* 96:755–759, 2002
16. Deyo RA, Battie M, Beurskens AJ, Bombardier C, Croft P, Koes B, et al: Outcome measures for low back pain research. A proposal for standardized use. *Spine* 23:2003–2013, 1998 (Erratum *Spine* 24:418, 1999)
17. Durrani Z, Winnie AP: Piriformis muscle syndrome: an underdiagnosed cause of sciatica. *J Pain Symptom Manage* 6:374–379, 1991
18. Fanucci E, Masala S, Sodani G, Varruciu V, Romagnoli A, Squillaci E, et al: CT-guided injection of botulinic toxin for percutaneous therapy of piriformis muscle syndrome with preliminary MRI results about denervative process. *Eur Radiol* 11:2543–2548, 2001
19. Filler AG: Imaging of peripheral nerve, in Katirji B, Kaminski H, Preston D, et al (eds): **Neuromuscular Disorders in Clinical Practice**. Boston: Butterworth-Heinemann, 2002, pp 266–282
20. Filler AG, Jabour B, Kliot M, Lufkin RB, Johnson JP: Magnetic resonance neurography: imaging characteristics of the sciatic nerve at the level of the piriformis muscle in patients with leg pain. *J Neurosurg* 86:416A, 1997 (Abstract)
21. Filler AG, Kliot M, Hayes CE, Saunders DE, Goodkin R, Bell BA, et al: Application of magnetic resonance neurography in the evaluation of patients with peripheral nerve pathology. *J Neurosurg* 85:299–309, 1996
22. Filler AG, Lufkin RB, Villablanca P: MR neurography & interventional MRI in diagnosis and treatment of sciatica from piriformis syndrome. *Eur Radiol* 7:1159A–1160A, 1997 (Abstract)
23. Filler AG, Maravilla K, Tsuruda JS: MR neurography and muscle MR imaging for image diagnosis of disorders affecting the peripheral nerves and musculature. *Neurol Clin* 22:643–682, 2004
24. Fishman LM, Dombi GW, Michaelsen C, Ringel S, Rozbruch J, Rosner B, et al: Piriformis syndrome: diagnosis, treatment, and outcome—a 10-year study. *Arch Phys Med Rehabil* 83:295–301, 2002
25. Fishman SM, Caneris OA, Bandman TB, Audette JF, Borsook D: Injection of the piriformis muscle by fluoroscopic and electromyographic guidance. *Reg Anesth Pain Med* 23:554–559, 1998
26. Freiberg AH: Sciatic pain and its relief by operations on muscle and fascia. *Arch Surg* 34:337–350, 1937
27. Freiberg AH, Vinke TH: Sciatica and the sacro-iliac joint. *JBJS* 16:126–136, 1934

28. Frymoyer JW: Lumbar disk disease: epidemiology. **Instr Course Lect** 41:217–223, 1992
29. Grant GA, Britz GW, Goodkin R, Jarvik JG, Maravilla K, Kliot M: The utility of magnetic resonance imaging in evaluating peripheral nerve disorders. **Muscle Nerve** 25:314–331, 2002
30. Grant GA, Britz GW, Goodkin R, Jarvik JG, Maravilla KR, Kliot M: Magnetic resonance imaging for peripheral nerve disorders, in Winn HR (ed): **Youman's Neurological Surgery**, ed 5. New York: WB Saunders, 2003, pp 3873–3888
31. Gupta R, Villablanca PJ, Jones NF: Evaluation of an acute nerve compression injury with magnetic resonance neurography. **J Hand Surg (Am)** 26:1093–1099, 2001
32. Heliövaara M, Mäkelä M, Knekt P, Impivaara O, Aromaa A: Determinants of sciatica and low-back pain. **Spine** 16:608–614, 1991
33. Howe FA, Filler AG, Bell BA, Griffiths JR: Magnetic resonance neurography. **Magn Reson Med** 28:328–338, 1992
34. Howe FA, Saunders D, Filler AG, McLean MA, Heron C, Brown MM, et al: Magnetic resonance neurography of the median nerve. **Brit J Radiol** 67:1169–1172, 1994
35. Jankiewicz JJ, Hennrikus WL, Houkom JA: The appearance of the piriformis muscle syndrome in computed tomography and magnetic resonance imaging. A case report and review of the literature. **Clin Orthop** 262:205–209, 1991
36. Jarvik JG, Yuen E, Haynor DR, Bradley CM, Fulton-Kehoe D, Smith-Weller T, et al: MR nerve imaging in a prospective cohort of patients with suspected carpal tunnel syndrome. **Neurology** 58:1597–1602, 2002
37. Jarvik JJ, Hollingworth W, Heagerty P, Haynor DR, Deyo RA: The longitudinal assessment of imaging and disability of the back (LAIDBack) study: baseline data. **Spine** 26:1158–1166, 2001
38. Jensen MC, Brant-Zawadzki MN, Obuchowski N, Modic MT, Malkasian D, Ross JS: Magnetic resonance imaging of the lumbar spine in people without back pain. **N Engl J Med** 331:69–73, 1994
39. Jordan SE, Ahn SS, Freischlag JA, Gelabert HA, Machleder HI: Selective botulinum chemodenervation of the scalene muscles for treatment of neurogenic thoracic outlet syndrome. **Ann Vasc Surg** 14:365–369, 2000
40. Kent DL, Haynor DR, Longstreth WT Jr, Larson EB: American College of Physicians, Position paper: Magnetic resonance imaging of the brain and spine: a revised statement. **Ann Intern Med** 120:872–875, 1994
41. Kent DL, Haynor DR, Longstreth WT Jr, Larson EB: The clinical efficacy of magnetic resonance imaging in neuroimaging. **Ann Intern Med** 120:856–871, 1994
42. Kline DG, Hudson AR, Kim DH: **Atlas of Peripheral Nerve Surgery**. New York: WB Saunders, 2001, p 309
43. Lasègue, C: Consideration sur la sciatique. **Arch Gén de Méd** 2:558, 1864
44. Long DM, BenDebba M, Torgerson WS, Boyd RJ, Dawson EG, Hardy RW, et al: Persistent back pain and sciatica in the United States: patient characteristics. **J Spin Disord** 9:40–58, 1996
45. Machleder HI, Moll F, Verity MA: The anterior scalene muscle in thoracic outlet compression syndrome. Histochemical and morphometric studies. **Arch Surg** 121:1141–1144, 1986
46. McCrory P, Bell S: Nerve entrapment syndromes as a cause of pain in the hip, groin and buttock. **Sports Med** 27:261–274, 1999
47. Mixter WJ, Barr JS: Rupture of the intervertebral disc with involvement of the spinal canal. **N Engl J Med** 211:210–215, 1934
48. Mizuguchi T: Division of the piriformis muscle for the treatment of sciatica. Postlaminectomy syndrome and osteoarthritis of the spine. **Arch Surg** 111:719–722, 1976
49. Moore KR, Tsuruda JS, Dailey AT: The value of MR neurography for evaluating extraspinal neuropathic leg pain: a pictorial essay. **AJNR Am J Neuroradiol** 22:786–794, 2001
50. North RB, Kidd DH, Zahurak M, Piantadosi S: Specificity of diagnostic nerve blocks: a prospective, randomized study of sciatica due to lumbosacral spine disease. **Pain** 65:77–85, 1996
51. Pace JB, Nagle D: Piriform syndrome. **West J Med** 124:435–439, 1976
52. Patrick DL, Deyo RA, Atlas SJ, Singer DE, Chapin A, Keller RB: Assessing health-related quality of life in patients with sciatica. **Spine** 20:1899–1909, 1995
53. Perry JR, Cohen WA, Jarvik JG: Radiology of the Spine, in Winn HR (ed): **Youmans Neurological Surgery**, ed 5. New York: WB Saunders, 2003, pp 504–505
54. Robinson DR: Piriformis syndrome in relation to sciatic pain. **Am J Surg** 73:355–358, 1947
55. Rodrigue T, Hardy RW: Diagnosis and treatment of piriformis syndrome. **Neurosurg Clin N Am** 12:311–319, 2001
56. Rossi P, Cardinali P, Serrao M, Parisi L, Bianco F, De Bac S: Magnetic resonance imaging findings in piriformis syndrome: a case report. **Arch Phys Med Rehabil** 82:519–521, 2001
57. Selim AJ, Ren XS, Fincke G, Deyo RA, Rogers W, Miller D, et al: The importance of radiating leg pain in assessing health outcomes among patients with low back pain. Results from the Veterans Health Study. **Spine** 23:470–474, 1998
58. Spinner RJ, Thomas NM, Kline DG: Failure of surgical decompression for a presumed case of piriformis syndrome. Case report. **J Neurosurg** 94:652–654, 2001
59. Stadnik TW, Lee RR, Coen HL, Neirynck EC, Buisseret TA, Osteaux MJ: Annular tears and disk herniation: prevalence and contrast enhancement on MR images in the absence of low back pain or sciatica. **Radiology** 206:49–55, 1998
60. Taylor VM, Deyo RA, Cherkin DC, Kreuter W: Low back pain hospitalization. Recent United States trends and regional variations. **Spine** 19:1207–1213, 1994
61. Tubiana R, Masquelet AC, Ma McCullough CJ, Fyfe IS, Klennerman L, Letournel E, et al: **Atlas of Surgical Exposures for the Upper and Lower Extremities**. London: Martin Dunitz, 2000
62. Vandertop WP, Bosma NJ: The piriformis syndrome. A case report. **J Bone Joint Surg Am** 73:1095–1097, 1991
63. Yeoman W: The relation of arthritis of the sacroiliac joint to sciatica, with an analysis of 100 cases. **The Lancet** 2:1119–1122, 1928

Manuscript received February 20, 2003.

Accepted in final form October 8, 2004.

Some portions of this report including illustrations have been presented in preliminary form as meeting abstracts and posters.

Current address for Dr. Farahani: National Cancer Institute, National Institutes of Health, Bethesda, Maryland.

Address reprint requests to: Aaron G. Filler, M.D., Ph.D., Institute for Nerve Medicine, 2716 Ocean Park Boulevard, Suite 3082, Santa Monica, California 90405. email: afiller@nervemed.com.